

RHINOLOGY

Endoscopic management of paediatric antrochoanal polyp: our experience

Trattamento endoscopico del polipo antro-coanale in età pediatrica: nostra esperienza

A.A. EL-SHARKAWY

Department of Otorhinolaryngology, Mansoura University, Mansoura, Egypt

SUMMARY

Antrochoanal polyp is a benign polypoid lesion arising from the oedematous mucosa of the maxillary sinus and extending through the maxillary ostium into the nose. In children, it constitutes 33% of all nasal polyps. Surgery is the usual treatment for antrochoanal polyps. The primary aim of treatment for antrochoanal polyp is complete removal with total clearance of the maxillary sinus. Herein, we present 36 cases of children with antrochoanal polyps (ACPs). All patients underwent preoperative radiological assessment by CT scan. All patients were subjected to uncinectomy and modified type III maxillary sinusotomy of the maxillary ostium for removal of the ACPs. Modified type III maxillary sinusotomy was performed by dilatation of the ostium of the maxillary sinus posteriorly, inferiorly and anteriorly. The most frequent presenting complaint was unilateral nasal obstruction, followed by rhinorrhoea. In 28 children, the polyps passed through the main ostium, while in 5 patients the polyp passed through the accessory ostium. In 3 children, the origin could not be assessed. The antral portion of the ACP was cystic in 3 patients and polypoidal in 33 cases. Recurrence was reported in 4 patients (11.1%) that were subjected to revision endoscopic sinus surgery. The follow-up period ranged from 12 months to 5 years with a mean of 3.5 years.

KEY WORDS: Antrochoanal polyp • Endoscopic management • Middle meatal antrostomy

RIASSUNTO

Il polipo antro-coanale è una lesione polipoide benigna che nasce dalla mucosa iperplastica del seno mascellare e raggiunge le fosse nasali attraverso l'ostio mascellare. Tale patologia rappresenta il 33% di tutte le poliposi nasali nei bambini. Il trattamento standard è considerato attualmente quello chirurgico, il cui obiettivo primario è un'asportazione radicale con la completa bonifica del seno mascellare. In questo articolo, presentiamo 36 casi di bambini affetti da polipo antro-coanale (ACPs). Tutti i pazienti sono stati sottoposti a una valutazione radiologica preoperatoria mediante esame TC. Per l'asportazione dei polipi è stato effettuato un intervento di rimozione del processo uncinato e antrostomia mascellare di tipo III modificato, che consiste nella dilatazione dell'ostio del seno mascellare posteriormente, inferiormente ed anteriormente. Il disturbo presentato più frequentemente dai pazienti era l'ostruzione nasale unilaterale, seguita dalla rinite. In 28 bambini il polipo impegnava l'ostio principale mentre in 5 pazienti passava attraverso l'ostio accessorio, mentre in 3 bambini non è stato possibile identificarne l'origine. La porzione antrale dei polipi antro-coanali si presentava cistica in 3 pazienti e polipoide in 33 pazienti. Si è osservata una recidiva di malattia in 4 pazienti (11, 1%), i quali sono stati sottoposti ad una revisione chirurgica endoscopica sinusale. Il periodo di follow up variava in un range tra 12 mesi e 5 anni con una media di 3,5 anni.

PAROLE CHIAVE: Polipo antro-coanale • Trattamento endoscopico • Antrostomia meato medio

Acta Otorhinolaryngol Ital 2013;33:107-111

Introduction

Antrochoanal polyps (ACPs), also known as Killian's polyps, are non-atopic, benign lesions that stem from the maxillary sinus, through its ostium (either the true ostium or accessory ostium) and extends to the choana¹.

Various pathogenic mechanisms have been proposed to explain the development of ACPs; however, their cause is still largely unknown and remains a topic of major debate². One study found a statistically significant association of allergy with ACPs³. However, another found that allergy has no role in the aetiology of ACPs, which may

be chronic inflammatory processes rather than allergy^{5,6}. Surgical treatment is the only feasible option for treatment of ACPs, and several techniques have been described². The Caldwell-Luc approach offers good exposure and ensures complete removal of the polyp and associated antral mucosa⁷. However, the Caldwell-Luc procedure may have side effects including cheek anaesthesia and swelling, and carries risks to developing teeth in children⁸. Since its introduction in nasal surgery, functional endoscopic sinus surgery (FESS) has become the gold standard for treatment of ACPs⁹. Several endoscopic techniques

have been described for removal of ACPs. Mini-Caldwell or transcanine surgeries have been reported to ensure the complete removal of the antral part of ACP in children. The aim of this study was to evaluate the use of minimally invasive endoscopy (uncinectomy with modified maxillary sinusotomy type III) for management of ACPs of the maxillary sinus.

Materials and methods

Ethical approval for this work was obtained (by the ethics committee in our ORL department in a tertiary care hospital). Informed consent was obtained from parents before endoscopic treatment of ACPs.

The study was conducted in the ORL department, Mansoura University hospital, Egypt, between 2006 and 2010. A total of 36 patients with ACPs were included. There were 22 males and 14 females with a mean age of 13.2 (range 9-17) years. Patient demographics are shown in Table I.

Preoperative assessment

All patients underwent preoperative radiological assessment by CT scan of the nose and paranasal sinuses with both axial and coronal cuts to document the extent of disease (Figs. 1, 2). Anatomical variants of the middle turbinate, dehiscence of the lamina papyracea and relation to the optic nerve were identified. Preoperative questionnaires on preoperative symptoms were obtained from patients or relatives (Table I).

Surgical procedure

Procedures were performed under general anaesthesia using a cuffed endotracheal tube with a hypotensive technique. Different angled rigid (0°, 30°, 70°) 4 mm endoscopes were used (2.7 mm endoscopes were not available during our study). Initial endoscopic examination of the nose was done with detection of the pedicle of the polyp coming from the middle meatus. Next, en bloc removal of

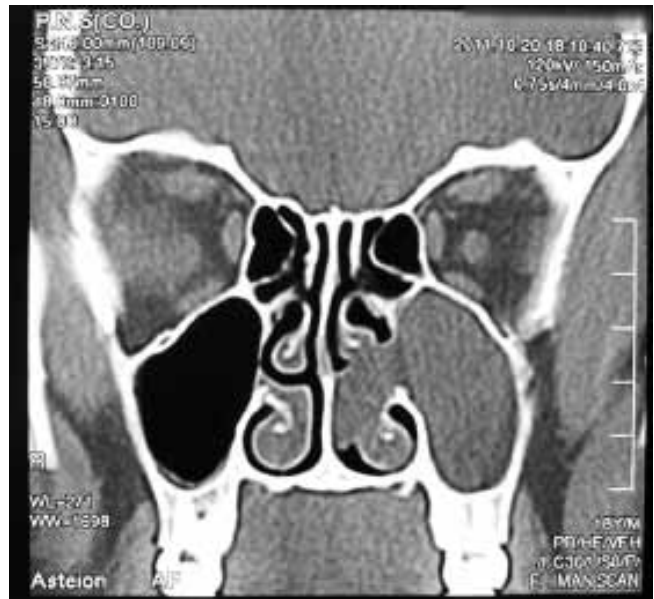


Fig. 1. Coronal CT image of an antrochoanal polyp on the right side.

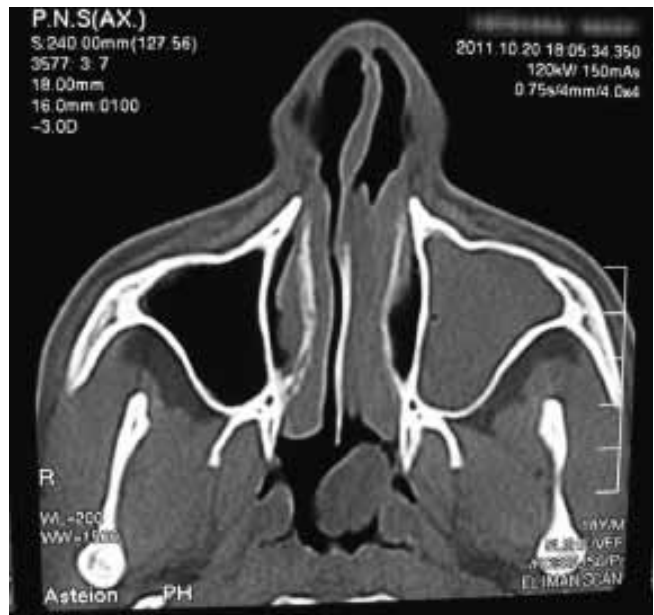

Fig. 2. Axial CT image of an antrochoanal with extension of the polyp to the nasopharynx.

Table I. Patient demographics and preoperative symptoms.

Characteristic	N (%)
Male	22 (61.1)
Females	14 (38.9)
Side	
Right	20 (55.5)
Left	16 (44.5)
Duration of symptoms	3 -24 months
Symptoms	
Nasal obstruction	36 (100)
Rhinorrhoea	26 (72.2)
Snoring/sleep apnoea	24 (66.6)
Headache	15 (41.6)
Epistaxis	10 (27.7)
Anosmia	7 (19.4)

the polyp was done by grasping the pedicle of the polyp with forward-cutting forceps. If the antral portion was too large for en bloc removal, the nasal portion was removed by first cutting the pedicle of the polyp. Uncinectomy was then performed by using backbiting forceps for excision of the lower portion of the uncinete process to expose the natural ostium of the maxillary sinus. Following this, modified type III sinusotomy of the maxillary ostium was performed as follows; by enlargement of the natural maxillary ostium posteriorly to a limited extent (< 1 cm), inferior to the base of the inferior turbinate and anteriorly by using a backbiting forceps. After dilatation of the natural

ostium, 30° and 70° endoscopes were used to inspect the origin and extent of the antral portion of ACPs. Through-cutting straight and angled forceps or angled shavers were placed through the maxillary ostium to carefully dissect and transect the origin of the polyp. The antral portion of the polyp was then removed through the widened maxillary ostium (Fig. 3). Care was taken to preserve any healthy sinus mucosa.

In most of patients, the nasal and nasopharyngeal parts of the polyp were removed transnasally, whereas if the nasopharyngeal portion was too large it was removed transorally (14 patients).

The maxillary sinus was thoroughly irrigated with warm normal saline solution through the maxillary ostium. All surgical specimens were sent for pathologic examination. Intranasal Merocele packs were inserted at the end of the surgery for 48 hours. Oral antibiotics were given for one week.

Associated pathologies (Table II)

Six patients had associated ethmoiditis with polyps, 4 had adenoid enlargement, 2 had inferior turbinate hypertrophy (deviated septum to the same side in one patient) and concha bullosa in one patient. These lesions were managed endoscopically while managing the ACPs.

Follow-up

After surgery, patients were reviewed in an outpatient clinic weekly for the first month, monthly for 3 next months and every 6 months during the follow-up period.

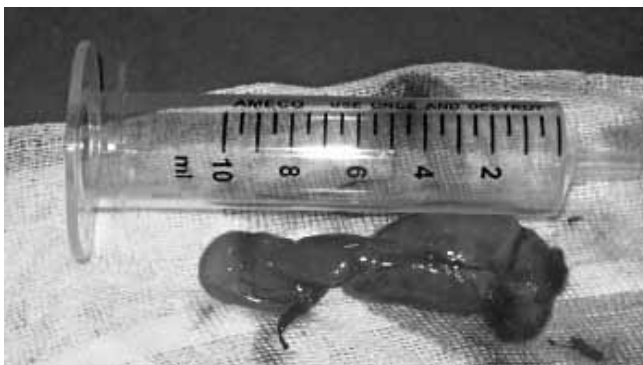


Fig. 3. The antrochoanal polyp, note the pharyngeal portion and nasal portion and isthmus in-between.

Table II. Associated concurrent nasal pathology.

Pathology	N (%)	Management
Ethmoiditis	12 (33.3)	Anterior ethmoidectomy
Hypertrophied inferior turbinate	7 (19.4)	Partial posterior end turbinectomy
Concha bullosa	5 (13.9)	Conchoplasty
Choanal adenoids	4 (11.2)	Endoscopic adenoidectomy
Septal spur	3 (8.3)	Localized endoscopic excision

Patients were instructed to use topical alkaline nasal wash frequently to minimize crust formation.

Endoscopic examination of the nose and maxillary antrostomy was done (without anaesthesia) at 3, 6, 12 and up to 24 months postoperatively. The follow-up period ranged from 12 months to 5 years with a mean of 3.5 years. Post-operative improvements of symptoms were determined during follow-up.

Results

Thirty-six children treated with endoscopic surgery for ACPs were included in this study. They were 22 males (61.1%) and 14 females (38.9%) with mean age 13.2 (9-17) years. The most frequent presenting complaint was nasal obstruction, followed by rhinorrhoea. Obstructive sleep apnoea syndrome or snoring was reported in 66.6% of children (Table I).

ACPs were on the right side in 20 patients (55.5%), and in the left side in 16 patients (44.5%). No bilateral ACPs were observed.

The origins and attachments of the pedicle in the antrum were as follows: posterior and lateral walls in 14 patients (38.9%); medial wall in 13 patients (36.1%) and inferior wall in 3 patients (8.3%). In 6 patients (16.6%), the exact origin was not detected as the antrum was filled with diffuse polypoidal mucosa.

Uncinectomy was done in 32 cases (88.9%) to expose the ostium of the maxillary sinus, while in 4 cases (11.1%) the uncinete process was too small or atrophied (and did not interfere with exposure of the maxillary ostium) most probably due to pressure atrophy by polyps.

In 28 children (77.8%), the polyps passed through the main ostium, while in 5 patients (13.9%) they passed through the accessory ostium. In 3 children (8.3%), the origin could not be assessed due to associated ethmoiditis.

All patients underwent modified type III maxillary sinusotomy for dilatation of the natural ostium of the maxillary sinus to allow manipulation the interior of the antrum for complete removal of the antral portion of the ACPs. The antral portion of the ACPs was cystic in 3 patients and polypoidal in 33 patients.

Complications occurred in 10 (27.8%) patients. Postoperative nasal adhesions were the most common complication reported in 6 patients (16.6%). Five of these 6 patients had adhesions between the inferior turbinate and nasal

septum. Only one patient had adhesion between the middle turbinate and lateral nasal wall due to associated ethmoidectomy. The nasal adhesions were minor in 5 patients with no detected effects on respiration, and patients received no treatment. The remaining patient had partial middle turbinectomy for treatment of the lateralized middle turbinate with adhesion.

Recurrence was reported in only 4 of 36 (11.2%) patients. Recurrences were seen at 6 months postoperative (one patient), 12 months (2 patients) and 1.5 year (one patient). Recurrent ACPs affected patients with unidentified origin of the polyps in the maxillary sinus (3 patients) and lateral wall (one patient). Diagnosis of recurrences was documented by rigid endoscope examination of the nose and CT scan of the nose and paranasal sinuses.

Recurrent ACPs originated from the lateral wall (2 patients), inferior wall (one patient) and anterior wall (one patient). Revision surgery was needed for all patients. Combined endoscopic sinus surgery with a transcanine approach was required for three patients whose polyps arose from the lateral and anterior wall. Endoscopic sinus surgery was done for the fourth patient. The maxillary ostium was stenosed in two patients and wide in two patients during revision surgery. No patients showed any recurrence of the ACPs until the end of this study.

Discussion

There are several options for management of antrochoanal polyps including simple polypectomy, Caldwell Luc's operation, endoscopic sinus surgery with middle meatal antrostomy and a combined approach (endoscopic endonasal surgery and mini-Caldwell Luc's). An endoscopic approach for complete removal of ACPs is extremely safe and effective ¹⁰.

The primary aim of FESS is complete removal of the polyp (both nasal and antral parts). Furthermore, it entails wide middle meatotomy connecting the natural and accessory ostium and, correction of any predisposing factors of an anatomical nature, such as septal deviations, spurs, turbinate hypertrophy or concha bullosa ².

Several modifications of the endoscopic technique had been advocated to allow complete excision of the ACP; endoscopic sinus surgery with middle meatal antrostomy, endoscopic endonasal surgery and mini-Caldwell Luc's, endoscopic sinus surgery with a transcanine approach, endoscopic sinus surgery with inferior meatal antrostomy and endoscopic sinus surgery with mega antrostomy ⁹⁻¹².

Nasal obstruction and rhinorrhoea were the most common preoperative symptoms in this study (100% and 72.2%, respectively). Recurrent epistaxis with no obvious causes was reported in 27.7% of cases. Epistaxis can be explained by recurrent infection of the polyp with some angiomatous changes in the surface of the polyp with recurrent bleeding ¹³.

Mega middle meatal antrostomy (type III sinusotomy) has been advocated by some authors to allow good ventilation to the sinus for complete the removal of polyps, and to avoid ostial stenosis to decrease the rate of recurrence ¹⁰. Classic type III sinusotomy was performed by dilatation of the maxillary ostium anteriorly up to the lacrimal bone, superiorly to just below the orbital floor, posteriorly to the

posterior wall of the maxillary sinus and inferiorly to the floor of the nose thus creating a wide antrostomy ¹⁰.

In this study, a modification of the classic type III sinusotomy was done. This modification entails dilatation of the natural ostium of the maxillary sinus anteriorly, posteriorly and inferiorly with no superior dilatation. Care was taken in posterior dilatation in a posterior direction no more than the posterior wall of the maxillary sinus to avoid injury of the branch of the sphenopalatine artery. This modification has many advantages; first it allows good visualization of the maxillary sinus for complete removal of the antral portion of the ACPs. Secondly, it avoids superior dilatation of the ostium to avoid orbital injury.

The degree of dilatation of the maxillary ostium is a point of controversy. Mendelson and Gross ¹⁴ advocated widening the ostia to 3-5 times its normal size, as well as creating an even larger mega-ostia for patients with ciliary abnormalities. On the other hand, many surgeons prefer a limited surgical technique (mini FESS) in paediatric patients, which is conservative and directed to the originating site of the disease ¹⁵.

There is controversy concerning the exit of the polyp from the maxillary sinus, where it is through the natural ostium or through an accessory ostium. In this study, in most cases the polyps passed through the main maxillary ostium in 28 cases, and through the accessory ostium in 5 cases. This concurs with results described other authors ²⁹.

The nature of the antral portion of ACPs is a point of debate, whether cystic or polypoidal tissue ¹²⁹. In this study, the antral part of the ACPs was cystic in only two cases and polypoidal in the remaining 34 patients. The cystic component of the polyp was detected by rupture of the cyst containing clear yellowish fluid. In these cases, careful dissection of the wall of the cyst was done to completely remove the polyp.

Recurrent ACPs are most probably due to regrowth of any missed residual polypoidal tissues within the maxillary antrum. Cook et al. ¹⁶ observed no recurrences in 33 patients with ACPs after FESS. Ozer et al. ¹⁷ performed FESS, combined with FESS and transcanine sinuscopy or the Caldwell Luc approach, for treatment of ACPs. They found recurrence in 3 patients after FESS, yet reported no recurrence after combined FESS and transcanine sinuscopy or the Caldwell Luc approach. Atighechi et al. ¹⁸ used a mini-Caldwell approach with FESS in their patients, and reported minimal recurrences and a low complication rate. Hong et al. ¹⁹ recommended powered instrumentation during FESS as an effective technique for removing ACPs and the antral portion. They found an improvement rate of 96.4% and no significant complications when powered instrumentation was used. In this study, recurrences were reported in 4 of 36 children (11.1%). These recurrences were attributed to incomplete removal of the antral portion of ACPs. A combined endo-

scopic and transcanine approach was used for complete removal of the antral portion of polyps arising from the lateral and anterior wall of the maxillary sinus. This agrees with Lee and Huang²⁰ who described a combined approach for polyps arising from the lateral and anterior wall.

Middle meatal antrostomy was stenosed in 2 patients during revision surgery. Although the incidence of middle meatal antrostomy stenosis after surgery is not known, Stankiewicz²¹ reported nearly a 50% incidence of antrostomy closure. In contrast, Lazar et al.²² found an incidence of stenosis of only 2%. Stenosis may result from extensive scarring in the middle meatus, recurrent polyposis or insufficient widening of the antrostomy during the initial surgery¹⁰.

Conclusions

Endoscopic sinus surgery with type III sinusotomy is a safe and effective procedure for removal of ACPs. It offers the following advantages: complete removal of the antral part of the polyp, treatment of concomitant pathologies in the maxillary sinus, preservation of healthy sinus mucosa for later epithelization of the sinus and treatment of an associated pathology in the ethmoidal region. Powered instruments and 30° and 70° angled endoscopes are essential for complete removal of ACPs.

References

- 1 Killian G. *The origin of choanal polypi*. Lancet 1906;2:81-2.
- 2 Frosini P, Picarella G, De Campora E. *Antrochoanal polyp: analysis of 200 cases*. Acta Otorhinolaryngol Itali 2009;29:21-6.
- 3 Cook PR, Davis WE, McDonald R, et al. *Antrochoanal polyposis: a review of 33 cases*. Ear Nose Throat J 1993;72:401-10.
- 4 Lathi A, Syed MM, Kalakoti P, et al. *Clinico-pathological profile of sinonasal masses: a study from a tertiary care hospital of India*. Acta Otorhinolaryngol Ital 2011;31:372-7.
- 5 Ozcan C, Zeren H, Talas DU, et al. *Antrochoanal polyp: a transmission electron and light microscopic study*. Eur Arch Otorhinolaryngol 2005;262:55-60.
- 6 Skladzien J, Litwin JA, Nowogrodzka-Zagorska M, et al. *Morphological and clinical characteristics of antrochoanal polyps: comparison with chronic inflammation-associated polyps of the maxillary sinus*. Auris Nasus Larynx 2011;28:137-41.
- 7 Schramm VL, Efferon MZ. *Nasal polyps in children*. Laryngoscope 1980;90:1488-95.
- 8 Woolley AL, Clary RA, Lusk RP. *Antrochoanal polyps in children*. Am J Otolaryngol 1996;17:368-73.
- 9 Kamel R. *Endoscopic transnasal surgery in antrochoanal polyp*. Arch Otolaryngol Head Neck Surg 1990;116:841-3.
- 10 Eladl HM, Shawky M. *Endoscopic surgery in pediatric recurrent antrochoanal polyp, rule of wide ostium*. Int J Pediatr Otorhinolaryngol 2011;75:1372-5.
- 11 El-Guindy A, Mansour MH. *The role of transcanine surgery in antrochoanal polyps*. J Laryngol Otol 1994;108:1055-7.
- 12 Ophir D, Marshak G. *Removal of the antral polyp through an extended nasooantral window*. Laryngoscope 1987;97:1355-7.
- 13 Robson AK, Barker CS, Whittet HB. *Epistaxis as an unusual presentation of an antrochoanal polyp*. J Laryngol Otol 1990;104:643-4.
- 14 Mendelsohn MG, Gross CW. *Soft-tissue shavers in pediatric sinus surgery*. Otolaryngol Clin North Am 1997;30:443-9.
- 15 Chang PH, Lee LA, Huang CC, et al. *Functional endoscopic sinus surgery in children using a limited approach*. Arch Otolaryngol Head Neck Surg 2004;130:1033-6.
- 16 Cook PR, Davis WE, McDonald R, et al. *Antrochoanal polyposis: a review of 33 cases*. Ear Nose Throat 1993;72:401-10.
- 17 Ozer F, Ozer C, Cagici CA, et al. *Surgical approaches for antrochoanal polyp: a comparative analysis*. B-ENT 2008;4:93-9.
- 18 Atighechi S, Baradaranfar MH, Karimi G, et al. *Antrochoanal polyp: a comparative study of endoscopic endonasal surgery alone and endoscopic endonasal plus mini-Caldwell technique*. Eur Arch Otorhinolaryngol 2009;266:1245-8.
- 19 Hong SK, Min YG, Kim CN, et al. *Endoscopic removal of the antral portion of antrochoanal polyp by powered instrumentation*. Laryngoscope 2001;10:1774-8.
- 20 Lee TJ, Huang SF. *Endoscopic sinus surgery for antrochoanal polyps in children*. Otolaryngol Head Neck Surg 2006;135:688-92.
- 21 Stankiewicz JA. *Complications of sinus surgery*. In: Bailey BJ, editor. *Head and Neck Surgery – Otolaryngology*. Philadelphia, PA: BJ Lippencott Co.; 1993. p. 413-26.
- 22 Lazar RH, Younis RT, Gross CW. *Pediatric functional endonasal sinus surgery: review of 210 cases*. Head Neck 1992;14:92-8.

Received: July 28, 2012 - Accepted: October 31, 2012